

# SPLIT CREST: IMMEDIATE EXPANSION RIM TECHNIQUE FOR REHABILITATION OF ATROPHIC MAXILLA: A CASE REPORT

## SPLIT CREST TECHNIQUE: A CASE REPORT

Deise Kersten Alves FERREIRA<sup>1</sup>; Carolina Amador da Silva CALANDRINI<sup>2</sup>; Wagner Almeida ANDRADE<sup>3</sup>

1 - Higher School of Amazonia, ESAMAZ, Belém, PA, Brazil

2 - Department of Implantology and Periodontics, Higher School of Amazonia, ESAMAZ, Belém, PA, Brazil

3 - Department of Oral and Maxillofacial Surgery, Belém, PA, Brazil

### SUMMARY

While the deploy planning, we come across morphological changes in the intervention area and the bone volume, which is extremely important for the treatment outcome. The objective of this study is to describe the technique "Split-Crest" through a clinical case in which success was obtained. Demonstrate indications and advantages of the technique in order to gain a significant increase in bone density to achieve an excellent aesthetic and functional result. Female patient, leucoderma, 46 years old, attended the Dental Clinic of Specialization in Implantodontics of ESAMAZ, with report of early teeth loss and poorly adapted prosthesis in the upper anterior region of the pre jaw. During the clinical evaluation was observed Edentulism in the anterior arch of the jaw. Total tomographic filming was done on the jaws, the initial diagnosis was a severe resorption present in the

premaxilla requiring regenerative process to achieve bone gain. During surgery the patient had immediate installation of previous implants in the region of the elements 12 and 22 through the technique of "Split-Crest", which consisted of two vertical cuts on the vestibular cortical portion and longitudinal osteotomy followed by the the shift vestibular cortical-spongy plate. Eight weeks later, the patient had clinically significant bone gain, proving the viability and success of the technique. A minimally invasive surgical procedure with well executed manipulation of tissue grafts and accelerates the clinical outcome, the working hours by the end of the treatment is smaller, has lower morbidity and lower operating costs.

Key Words: Dental implants; split crest; osteotomy; rehabilitation; atrophic maxilla.

### INTRODUCTION

The rehabilitation of patients with insufficient bone quantity has been one of the challenges of implant dentistry. After the loss of enamel organ begins the alveolar ridge remodeling process. This remodeling affects first the bone thickness, which can compromise the prosthetic rehabilitation on dental implants<sup>1</sup>.

In an attempt to increase lip volume, certain surgical procedures may be performed before or simultaneously with the implant placement. The technique of division and expansion of the residual ridge has been used as an alternative method to prepare the atrophic maxilla and mandible for implant insertion. Originally developed by Tatum in 1986, and later modified by Simon *et al.*, in 1992 the technique achieves an immediate increase in the thickness of the alveolar ridge with simultaneous placement of implants<sup>2</sup>.

The techniques commonly used for correction of horizontal defects of the alveolar crest are guided bone regeneration (GBR) with xenografts and membrane; autografts, that may be of intra oral origin and the region of mento or the jaw branch and extra oral taken from the iliac crest or skullcap; Horizontal Bone distraction that will be documented in this clinical case<sup>1</sup>.

This scientific article aims to present and report the technique of Split Crest, which has been achieved successful treatment with increased thickness of the front edge and immediate implant placement, showing indications and benefits for a significant increase in bone density. The technique consists in making a

longitudinal fracture on the edge, dividing it into two parts. This procedure involves the preparation of a partial osteotomy of the vertical ridge, following the palatal cortical which, being denser, limits the amount of expansion. The cortical bone is easily expanded, being moved laterally with the consequent increase of the ridge width<sup>3</sup>.

It is required, for the use of this technique, an interposition between the cortical cancellous bone buccal and lingual / palatal, to facilitate the introduction of instruments between the two cortical. Medullary bone ensures elasticity to the bone tissue, which is important during the surgery time in order to occur so-called "green stick fracture" and not a total possible fracture of the bone cortex<sup>4</sup>.

The empty space obtained from cortical, diastase, can be filled with particulate autogenous bone tissue, biomaterial or only with blood clot. The main factor for the choice of material that will be used is the size of the space to be filled, since the bone defect created is extremely favorable to repair<sup>5,6,7</sup>.

In a study by Scipioni *et al.*<sup>7</sup>, In 1999 it was discovered a great osteogenic activity in the expanded area. The authors suggested that the space created by osteotomy in the flange undergoes a spontaneous ossification, the new formed bone allows the consolidation of the buccal wall and the palatal / alveolar tongue and that this surgical procedure favors an optimal bone formation expanded space.

The amount of expansion obtained should allow the installation of implants with appropriate size to receive a prosthesis contour and appropriate biomechanical properties<sup>8,9</sup>. Simultaneous installation of the implants results in shorter treatment duration, less morbidity and therefore less cost to the patient<sup>10</sup>.

So the technique should be well suited to achieve the desired success of treatment with implant osseointegration, a suitable prosthesis and patient satisfaction.

**CASE REPORT**

Patient O.E.A.S., 46 years old, female, systematically healthy sought care in Clinic of Implant Dentistry Specialization at ESAMAZ (Escola Superior da Amazônia) to make prosthetic rehabilitation with dental implants in the jaw region. In the

clinical evaluation was observed edentulism in the anterior maxillary arch and the presence of the lower dental elements.

Total tomographic filming of the jaws was done, the initial diagnosis was a severe resorption present in the premaxilla requiring regenerative process was conducted in order to achieve bone gain. Despite the wide crest to be insufficient and the rim present a significant buccal defect, the cortical plates, vestibular and palate had interposition of medullary tissue, which characterizes a situation favorable to employment of the proposed technique.

The mobile prosthesis was used as a temporary prosthesis and two were made of the same for the purpose of using one as a surgical guide. The surgical technique consists primarily of oral intra antiseptics with chlorhexidine 0.2% and local infiltration anesthesia. The local anesthesia with the

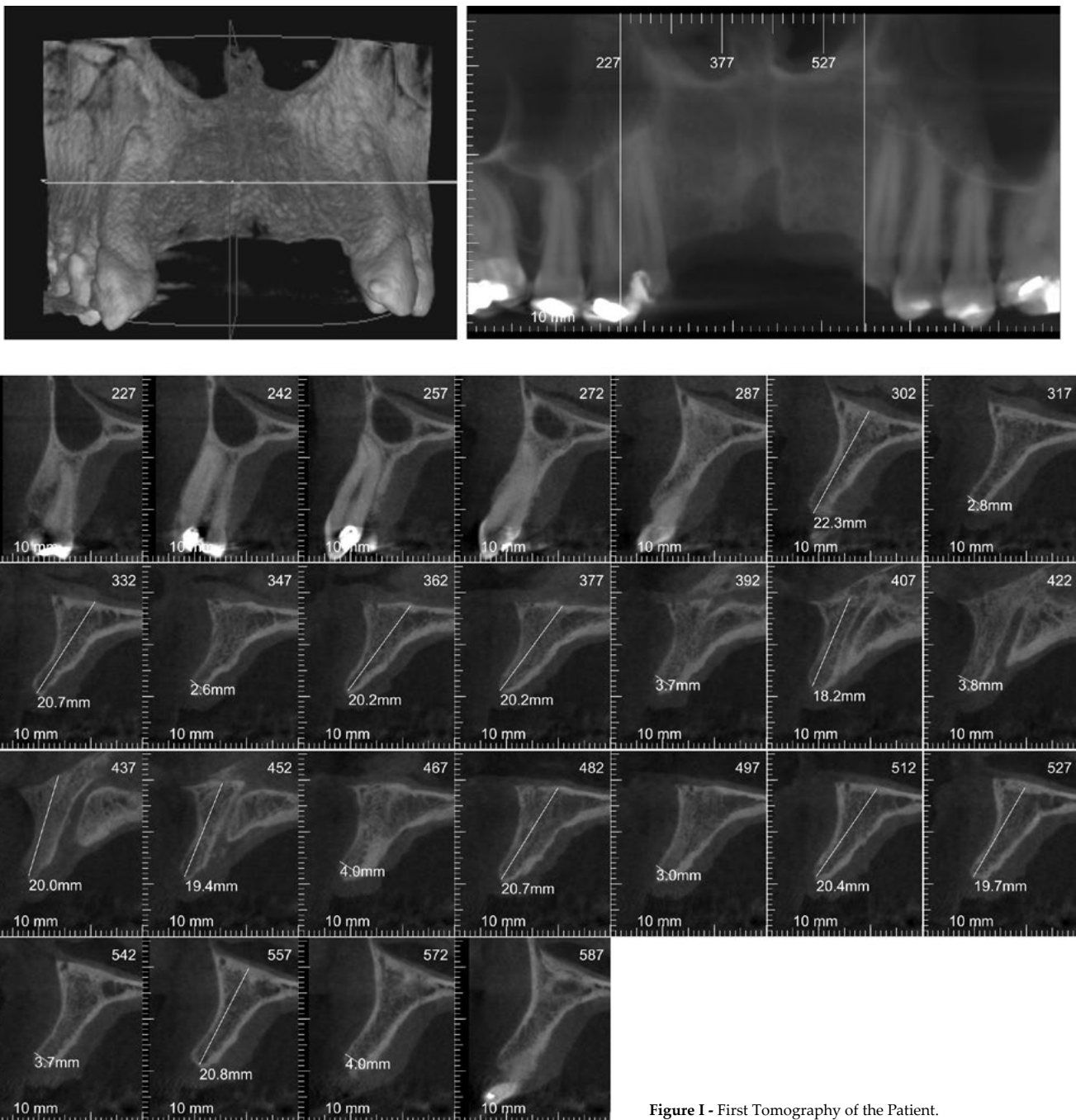


Figure I - First Tomography of the Patient.

benzodiazepine Alprazolam 0.25 mg (Salutas Pharma GmbH, Barleben, Alemanha) was also performed for patient comfort. After local anesthesia with 4% Articaine (DFL LTDA, Rio de Janeiro-RJ, Brazil), an incision was made along the edge of the crest, in keratinized mucosa, providing the displacement of the flap in its local thickness. In this shift, as well as muscle insertion, especially for college entrance flange, the procedure is the displacement of the palatal mucosa intended to facilitate the viewing of its anatomy.

In this surgical time we have tried to remove fibrous inserts in the bone surface. To start the osteotomy was used a small surgical disk 3mm, using as reference the incisive canal and extending to distal 3mm canine patient. Then we proceeded to the bone osteotomy gap with the help of chisels and expanders building on the piriform cortex nasal cavity.

The advancement of the blade, through the bone, was carried out with the aid of a hammer deep enough to move the coronal cortical and have access to medullary bone. The length of the osteotomy along the edentulous ridge, extended beyond the area of the planned implants, allowing the expansion needed for insertion of the implants.

Finished the osteotomy, they used the thin chisels to promote the separation of cortical and start gentle ridge split. With the edge already expanded, we performed the conventional protocol to prepare the receptor site, 3mm to 4mm of intact bone in the apical region, for the installation of the implant in region 12 and 22. Before insertion of implants, a depth gauge was used to detect any drilling, fenestration or dehiscence of the cortical bone. The insertion was performed gradually, in a slow and careful way to expand the rim and accommodate the diameter of the planned implant.

The preparation of surgical alveolus was performed at 1200 rpm under continuous cooling with saline. We obtain a

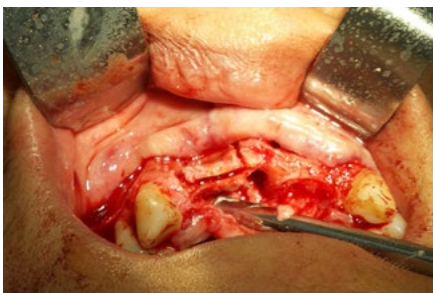
minimum distance of 3mm from the mesial root of the canine, respecting the bone limit. The direction of drilling has taken into account the direction of a guide, favoring the biomechanics of future rehabilitation and the desire of the prosthesis. There was a undersizeddrilling and subsequently increased the surgical alveolus with bone expanders.

The implants were installed at low rpm to 48 rpm, with the parameter of settlement level at 1mm beyond the bone crest. On the tooth region 22 a Titanium Fix AS Technology implant of 3.3x150 mm (manufactured in São José dos Campos, São Paulo, Brazil) was inserted and on the tooth region 12 a Titanium Fix of 3.75x15.0 mm external hexagon platform. Then the procedure was followed by bone graft installation with Bio-oss. Geistlich Pharma (Bahnhofstrasse 40 6110 Wolkhusen Switzerland) Spongiuous Ganules 0.25mm-1mm in bone gaps and cover with collagen membrane Gen-derm Baumer S/A (Mogi Mirim, São Paulo, Brazil) Biological membrane of bovine origin - small 20x20mm. After two months, when the patient returned, one can already clinically notice bone gain in the operated area.

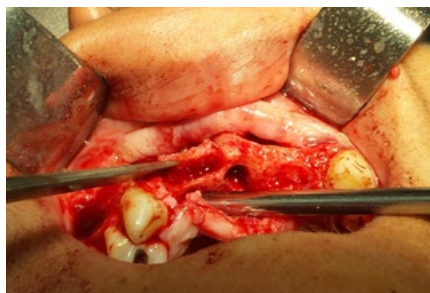**DISCUSSION**

The surgical expansion technique of the rim can be a useful method the reconstruction thickness of the residual ridge, for installation mediately or immediately implants. This technique is considered less invasive, require a shorter rehabilitation and has a lower cost compared to bone grafts and membranes.

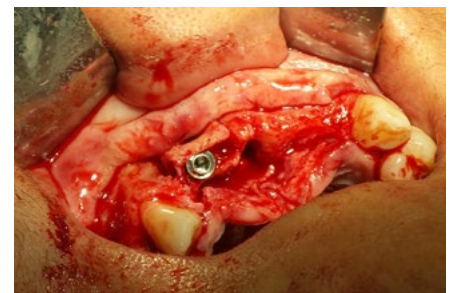
The reason may lie in the type of bony ridge where this technique can be applied, which should be considered to increase the rim only occur horizontally. The technique should only be applied when the buccal and lingual / palatal walls are separated by medullary bone<sup>7,11,12,13,14,5,16</sup>.



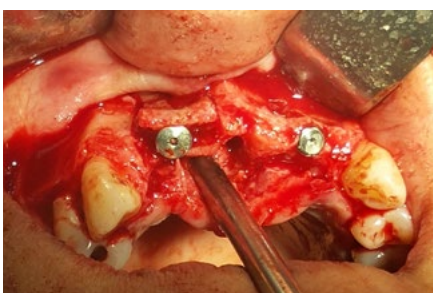**Figure II** - Osteotomy made with a small surgical disk of 3mm, using as reference the incisive canal and extending to the distal 3mm of the canine tooth.



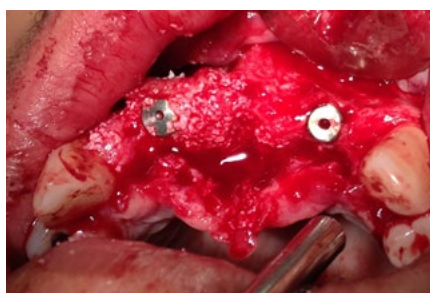
**Figure III** - Opening bone osteotomy with the help of chisels and expanders building on the piriform cortex nasal cavity.



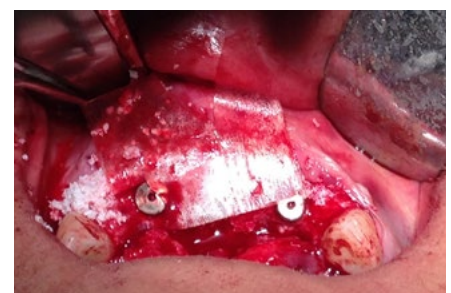**Figure IV** - The implant 1 mm beyond the bony ridge in the 12 region, set in primary stability Titanium Fix® of 3.75x15.0 mm External Hexagon platform.



**Figure V** - In the region region 22 a Titanium Fix® AS Technology (manufactured in São Jose dos Campos, São Paulo, Brasil) de 3.3x15.0 mm implant.



**Figure VI** - Bone graft installation with Bio-oss®. Geistlich Pharma Spongiuous Granules 0.25mm-1mm in bone apertures.



**Figure VII** - Cover with collagen membrane Gen-derm® Baumer S/A Biological membrane of bovine origin - small 20x20mm.

Therefore, the indications are more limited when compared to other techniques. For proper installation of the implants it is important to use surgical guide that can help prevent unfavorable inclinations and achieve primary stability. Some authors state that, for the implant to achieve perfect primary stability, it is necessary to prepare from 3mm to 4mm of intact bone in the apical region<sup>2,17</sup>.

The literature states that the flange can be expanded with the use of various techniques and surgical osteotomies instruments. The most prevalent technique studied was that of longitudinal fracture in "green stick" or "Split crest" of the buccal bone wall, where two parallel bone incisions in the buccal bone wall were joined by an incision in the bone crest<sup>5,18,19</sup>.

The case presented used the expansion technique of the alveolar ridge combined with bone grafts and / or membranes as reported by authors such as Simon *et al.*<sup>2</sup>, in 1992, Engelke *et al.*<sup>18</sup>, 1997; Wijs and Cune<sup>11</sup>, 1997.

The technique has many advantages over different techniques, it takes advantage of the inherent flexibility quality of cancellous bone. Jawbone is flexible and can be manipulated slowly to improve the quality (compression and corticalization) and expand to the desired width. It works fairly well the upper jaw bone as compared to the mandible, being more porous bone, especially D2, D3 and D4<sup>20</sup>.

But there are some disadvantages to this technique. It can not reach vertical bone height. For the surgeon performing the procedure is necessary skill and substantial learning curve. It is more difficult to perform on a single tooth than in large toothless areas where the operator can take advantage of the elasticity of a long bone crest<sup>20</sup>.

We consider this case a success because the implants are considered satisfactory if they presented no discomfort to the patient (such as pain), absence of peri-implant infection with suppuration, lack of mobility and radiolucency around the implant.

The Split crest technique is a bone enhancement procedure, trustworthy and reliable when properly indicated and well planned. The end result proved satisfactory, achieving the desired objectives in the aesthetic and functional point of view. Reducing discomfort, morbidity, labor costs and providing quality solutions for the patient.

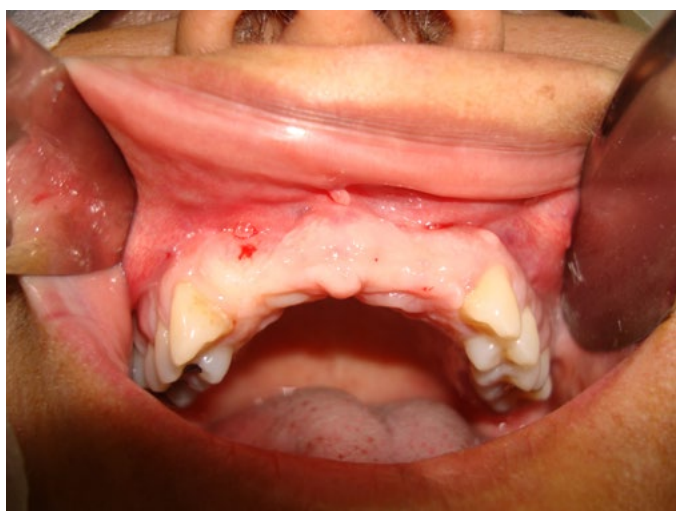

Figure VIII - Initial appearance of the patient.

## REFERENCES

01. Rocha S. Horizontal bone distraction. *Dental Team Magazine*. v. 6 p. 28-37, 2013.
02. Simion M, Baldoni M, Zaffe D. Jawbone enlargement using immediate implant placement associated with a split-crest technique and guided tissue regeneration. *Int J Periodontics Restorative Dent* 1992;12(6):463-73.
03. Misch CM. Implant site development using ridge splitting techniques. *Oral Maxillofac Surg Clin North Am* 2004;16:65-74.
04. Chiapasco M, Romeo E. Oral rehabilitation with implant-supported prosthesis for complex cases. Santos; 2007. p. 237-45.
05. Scipioni A, Bruschi MD, Calesini G. The edentulous ridge expansion technique: a five-year study. *Int J Periodontics Restorative Dent* 1994;14(5):451-9.
06. Scipioni A, Bruschi GB, Giargia M, Berglundh T, Lindhe J. Healing at implants with and without primary bone contact. *Clin Oral Implants Res* 1997;8:39-47.
07. Scipioni A, Bruschi GB, Calesini G, Bruschi E, De Martino C. Bone regeneration in the edentulous ridge expansion technique: histological and ultra structural study of 20 clinical cases. *Int J Periodontics Restorative Dent* 1999;19(3):269-77
08. Misch CE. Divisions of available bone. In: Misch CE (ed). *Contemporary implant dentistry*. St. Louis (MO): Mosby; 1999. p.98-9.
09. Triplett RG, Schow SR. Autologous bone grafts and endosseous implants. *Complementary techniques*. *Int J Oral Maxillofac Implants* 1996;54:486-94.
10. Kayatt FE, Perez DS, Mosele OL, Mosele Jr. OL. Expansion of the alveolar process with sagittal split osteotomy for insertion of dental implants with a saw and chisel - Case report. *Innovations Implant Journal* 2006;30-4.
11. Wijs F, Cune MS. Immediate labial contour restoration for improved esthetics: a radiographic study on bone splitting in anterior single-tooth replacement. *Int J Oral Maxillofac Implants* 1997;12(5):686-96.
12. Spicioni A. *et al.*, Bone regeneration in the edentulous ridge expansion technique: histological and ultra structural study of 20 clinical cases. *Int. J. Period. Rest. Dent.*, v. 19, p. 269-77, 1999.
13. Sethi A, Kaus T. Maxillary ridge expansion with simultaneous implant placement: 5-year results of an ongoing clinical study. *Int J Periodontics Restorative Dent* 2000;15(4):491-9.

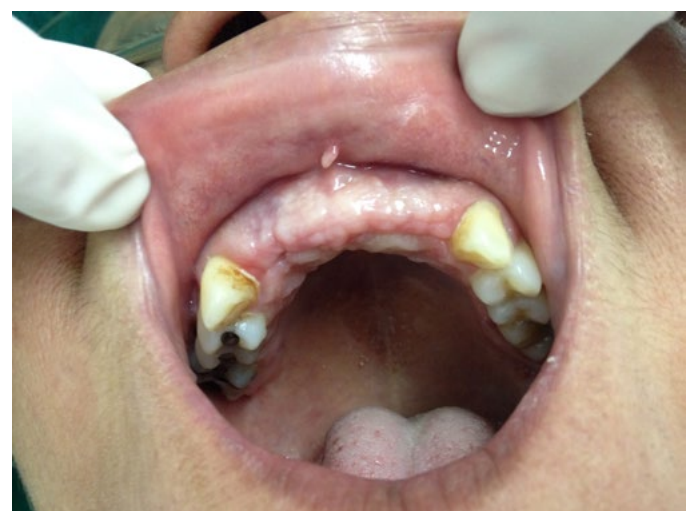

Figure VIII - Appearance of the patient's rim two months after surgery.

14. Malchiodi L. *et al.*, Rigid fixation by means of titanium mesh in edentulous ridge expansion for horizontal ridge augmentation in the maxilla. *Int. J. oral. Maxillofac. Impl.*, v. 13, n. 5, p. 701-5, 1998.
15. Davarpanah M. *et al.*, The modified osteotome technique. *Int. J. Period. Res. Dent.*, v. 21, n. 6, p. 599-607, 2001.
16. Oikarinen K. S. *et al.*, Augmentation of the narrow traumatized anterior alveolar ridge to facilitate dental implant placement. *Dent. Traumatol.*, v. 19, n. 1, p. 19-29, 2003.
17. Basa S, Varol A, Turker T. Alternative bone expansion technique for immediate placement of implants in the edentulous posterior mandibular ridge: a clinical report. *Int. J. oral Maxillofac. Impl.*, v. 19, n. 4, p. 554-8, 2004.
18. Engelke W, *et al.*, Alveolar reconstruction with splitting osteotomy and microfixation of implants. *Int. J. oral Maxillofac. Impl.*, v. 12, n. 3, p. 310-8, 1997.
19. Coatoam G, Mariotti A, The segmental ridge-split procedure. *J. Periodontol.*, v. 74, n. 5, p. 757-70, 2003.
20. Mayur S. Khairnar, *et al.*, Modified ridge splitting and bone expansion osteotomy for placement of dental implant in esthetic zone. *Contemp Clin Dent.* v. 5 p.110-114, 2014.

---

## RESUMO

Durante o planejamento do caso, foram encontradas alterações morfológicas na área de intervenção e do volume ósseo, que se torna extremamente importante para o resultado do tratamento. O objetivo deste estudo é descrever a técnica "Split-Crest" através de um caso clínico em que o sucesso foi alcançado. Assim, demonstrar indicações e vantagens da técnica, a fim de obter um aumento significativo na densidade óssea para obter um excelente resultado estético e funcional. Paciente do sexo feminino, leucoderma, 46 anos, procurou a Clínica de Especialização em Implantodontia da ESAMAZ, com relato de perda precoce de dentes e prótese mal adaptada na região anterior superior da pré-maxila. Durante a avaliação clínica foi observado o edentulismo no arco anterior da mandíbula. Solicitou-se uma Tomografia Computadorizada dos maxilares, e o diagnóstico inicial

foi uma reabsorção grave presente na pré-maxila que requer processo regenerativo para obter ganhos ósseos. Durante a cirurgia, o paciente apresentou instalação imediata de implantes anteriores na região dos elementos 12 e 22 por meio da técnica de "Split-Crest", que consistiu em dois cortes verticais na porção cortical vestibular e osteotomia longitudinal seguido pela cortical vestibular - placa de repouso. Oito semanas depois, o paciente apresentou ganho ósseo clinicamente significativo, provando a viabilidade e o sucesso da técnica. Um procedimento cirúrgico minimamente invasivo com manipulação bem executada de enxertos de tecido e acelera o resultado clínico, tempo clínico menor, menor morbidade e menores custos operacionais.

Palavras-chave: Implantes dentários; Osteotomia; Reabilitação; Maxila atrófica.

---

## AUTHOR FOR CORRESPONDENCE

Name: Deise Kersten Alves Ferreira

Address: Rodovia dos Trabalhadores 1750 – Avenida Esmeralda 55 CEP: 66640-590, Belém, Pará, Brazil.

Tel: +55. 91. 98346-4111.

Email: deisekferreira@gmail.com