

BICHECTOMIA, A SIMPLE AND FAST SURGERY: CASE REPORT

BICHECTOMIA, UMA CIRURGIA SIMPLES E RÁPIDA: RELATO DE CASO

Roservaldo MOREIRA JÚNIOR¹; Gabriela GONTIJO²; Tainá Carvalho GUERREIRO³; Roosevelt MOREIRA⁴; Neidison Luiz de SOUSA⁵

1 - Mestre em Implantodontia, Doutorando em CTBMF, Pós-graduado em Implantes Guiados, Habilitado em Sedação Consciente e Professor do curso de especialização em Implantodontia no Instituto Roservaldo Moreira. Faculdade Sete Lagoas- FACSET;

2 - Graduada em odontologia. Universidade Federal de Goiás- Faculdade de Odontologia- FO/UFG;

3 - Bióloga e Mestre em Biologia da Relação Parasito-Hospedeiro. Faculdade Sete Lagoas- FACSET;

4 - Pós-graduando em Dentística e implantodontia. Faculdade Sete Lagoas- FACSET;

5 - Pós-graduado em ortodontia e mestre em ortodontia. Faculdade Sete Lagoas- FACSET.

ABSTRACT

Bichectomy is an intra oral surgical procedure, which is the excision of Bichat's fat pad, in order to make the patient's face thinner and bring to him/her greater harmony in the facial contour. The surgery is simple, fast, has a low rate of postoperative complications and can be performed by dental surgeons or plastic surgeons. This article will present a case

report of a bichectomy procedure conducted by a dental surgeon on a female patient. The aesthetic results of this procedure can be effectively observed after a period of 4 to 6 months, when the swelling of the subcutaneous tissue is completely resorbed.

KEYWORDS: Bichectomy; Cheek Surgery; Bichat's Fat Pad.

INTRODUCTION

Bichectomy is the name given to the surgical procedure which objective is the resection of the buccal adipose body, removing the corresponding part of the Bichat's fat pad, which is around 30 to 40% of this structure¹. This procedure results in the reduction of the volume in the middle third of the face, tapering the patient's face, giving him/her greater harmony in the facial contour. The buccal adipose body was described in 1802 by Marie François Xavier Bichat, an anatomist, physician and biologist².

The Bichat's fat pad consists of a spherical fat mass, encapsulated by a thin layer of connective tissue, located externally to the buccinator muscle and the anterior edge of the masseter muscle³. It presents pyramidal shape, spreading itself to the masseteric area, superficial and deep temporal areas, pterygomandibular area, sphenopalatine area, and inferior orbital area⁴.

Especially prominent in newborns, it is believed that this structure performs functions such as assisting in the suction during breastfeeding preventing the collapse of the cheeks⁵, and protecting neurovascular structures of the face. In adults, the buccal adipose body volume is relatively consistent, and persists resistant even in cases of weight loss and loss of subcutaneous fat⁶.

This surgical procedure is indicated for individuals who have the middle third of the face more prominent than the zygomatic bone, giving them an excessive facial roundness, with heavy and inharmonious aspect. In this way, the excision of Bichat's fat pad can enhance the facial contour of the patient, providing a thinner appearance to the cheeks, within a harmonious balance⁷.

This technique is indicated for aesthetic purposes and has spread among several countries in recent years, becoming a trend especially among women. However, there are few scientific papers published about bichectomy. Therefore, the

aim of this article is to demonstrate, through the presentation of a case report, the surgical method and its post-recovery effect on facial aesthetics of the evaluated patient, and consequently, come to add to the scientific body on the subject.

CASE REPORT

A 27-year-old patient, female, with good general health, sought dental care to perform facial aesthetic procedure, seeking to reduce the volume of the middle third of her face. The patient's main complaint was that she was uncomfortable with the volume of her cheeks. After making the photographic protocol for facial analysis, the bichectomy (Bichat's fat pad removal) was indicated.

The antibiotic prophylaxis was performed with 1 gram Amoxicillin and 8 milligram Dexamethasone administered one hour before the procedure. It was performed intraoral disinfection with Chlorhexidine Digluconate 0.12%, and extraoral disinfection with Chlorhexidine Digluconate 2%, as well as subperiosteal local anesthesia with the anesthetic Mepivacaine 2% (DFL, SP, Brazil) with subsequent blockade of posterior superior alveolar nerve, and with small additions near the region to be incised in order to get the benefits of the vasoconstrictor.

The access to Bichat's fat pad was made intraorally through a horizontal incision of about 1 cm with Scalpel Handle No. 3 (Quinelato, SP, Brazil) and Scalpel Blade No. 15c (Swann-Morton, Sheffield, England), parallel to the duct output of the parotid gland (Figure 1).

The divulsion was made in the area with blunt tip instrument, Kelly tweezer 14mm (Quinelato, SP, Brazil), to obtain access to the fat capsule and to detach the Bichat's fat pad with smooth rotational movements of the Kelly tweezer, without traction

excess. Gradually, all the fat capsule was pulled to its excision (Figures 2.a and 2.b).

The portion of the fat that was projected was seized, clamped at its base, and excised with Iris scissors 11.5 cm (Quinelato, SP, Brazil) (Figure 3).

In order to ensure the facial symmetry of the patient, it was evaluated the volumes removed from the capsules of fat on each side of the face, with precision scale (Tangent, China) (Figure 4).

The synthesis was performed with simple stitches dual-node using a resorbable and needled suture thread, Monocryl 4.0 (Ethicon, SP, Brazil) (Figure 5).

For postsurgical it was prescribed 500 milligram Amoxicillin, 600 milligram Ibuprofen and 500 milligram Dipyron. It was indicated intense cryotherapy in the first 24 to 48 hours after the procedure. Returns were scheduled for follow-up of 7 days, 1 month and 6 months.

During the first month of monitoring, the patient did not report feeling painful symptoms and clinically showed good healing, absence of inflammation and mild signs of facial edema.

Six months after the surgery, there was complete disappearance of edema and great satisfaction by the patient with the results. (Figures 6.a, 6.b, 6.c, 6.d, 6.e and 6.f).

DISCUSSION

The bichectomy is a simple, and safe procedure, performed under local anesthesia, which lasts about 25 to 35 minutes, from the application of the anesthetic to the suture. However, it is important that the surgeon explain all matters relating to this surgery, such as the aesthetic potential for each patient, the irreversibility of the technique, the costs and other factors, such as risk of bleeding and infection⁷.

In order to undergo this surgical procedure, patients must be over eighteen years old, physically fit, non-smokers and aware and realistic about the objectives and results that can be achieved with bichectomy⁷.

During the surgical procedure it should only be removed the fat capsule that juts without excessive traction and cautiously, resecting only what easily juts with light pressure through gentle movements^{6,7}. Lastly, bichectomy should be conducted carefully in order to avoid the facial nerve injury and disruption of the fascia surrounding the fat capsule⁷.

Some problems and rare complications can occur during surgery, such as injuries on the Stensen duct⁸ and on the buccal branch of the facial nerve, manifested as salivary fistula and temporary numbness of the buccal nerve⁷. Other complications such as hematomas and infections can occur, but they are potential problems in any surgery.

The high precision balance is a device used in order to ensure that the amount of fat removed is similar on both sides of the face, assisting in obtaining facial symmetry and minimizing possible irreversible errors during the surgical procedure.

There are no formal nominations for sending the samples for anatomopathological and histologic examination, unless any different macroscopically aspect is observed, such as changing color and/or size of blood vessels⁷.

Comparing multifilament yarns with monofilament yarns it is usually observed more favorable tissue reaction to monofilament yarns due to less possibility of bacterial retention⁹.

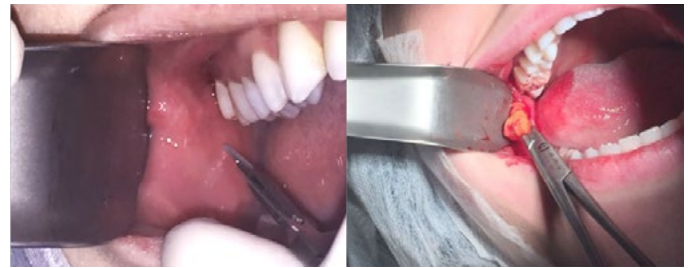

Figure 1 - intraoral incision of 1 cm, parallel to the duct output of the parotid gland. Figure 2.a - initiation traction of the Bichat's fat pad.

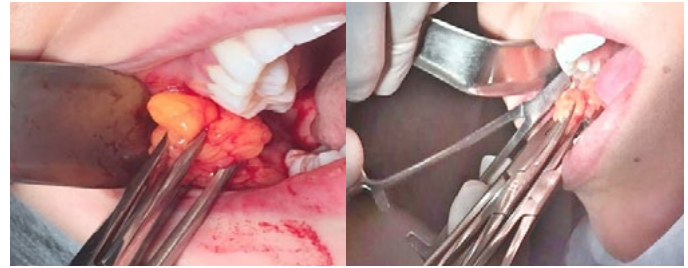
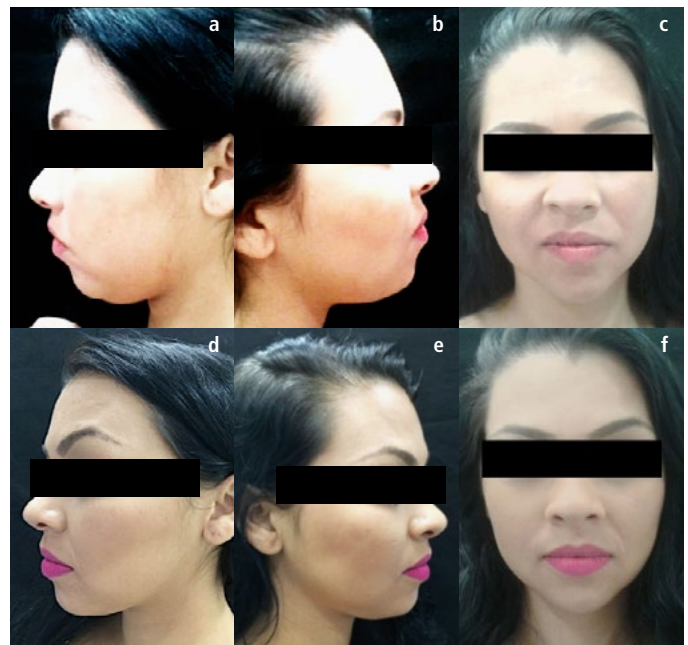


Figure 2.b - Divulsion of the Bichat's fat pad. Figure 3 - Excision with Iris scissors fat pad with Kelly tweezers.

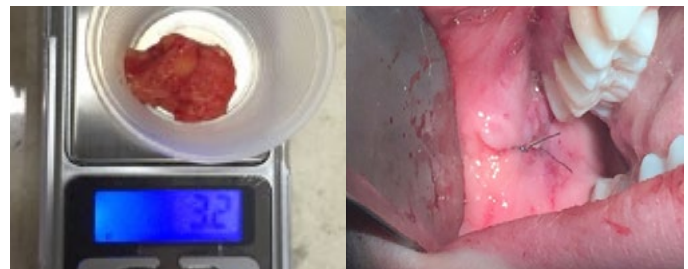

Figure 4 - Fat weighing on a precision scale. Figure 5 - Synthesis



Figures 6 a, b and c - Initial photos left, right and front profile of the patient. Figures 6 d, e and f - Follow-up 6 months after bichectomia

The monocryl was used in this patient because it is a monofilament yarn and has lower bacterial accumulation, which favors healing, and because it is resorbable, it provides greater comfort after surgery, since it does not require a stitch removal procedure.

Cryotherapy consists of any form of application of objects that cause cooling of tissues for therapeutic purposes¹⁰. The capillary vasoconstriction cold-induced causes a reduction in blood flow and consequently the blushing, the heat and the tumor of the treated tissues¹¹. The therapeutic cold applied to the lesion site aims to act as a modulator of the inflammatory response, in order to reduce facial edema caused by bichectomy.

After removing the Bichat's fat pad, the final results can be effectively observed after 4 to 6 months, when the swelling of the soft tissue is definitely resorbed^{6,7}. However, the patient of this study noticed satisfactory results in the period of 30 days after the surgery.

CONCLUSION

The bichectomy is a surgery with aesthetic purposes, simple and secure which objective is to enhance facial contour giving the patient a slimmer and harmonious face.

Despite the simplicity and fast postoperative recovery of this surgical procedure, there are few scientific studies on the subject. Requiring new studies that will add information to the body of evidence about bichectomy, and disseminate the techniques used during this surgery, promoting the exchange of knowledge among professionals.

REFERENCES

01. Stuzin JM, Wagstrom L, Kawamoto K, Baker TJ, Wolfe SA. The anatomy and clinical application of the buccal fat pad. *Plast Reconstr Surg.* 1990; 85(1): 29-37.
02. Shoja MM, Tubbs RS, Loukas M, Shokouhi G, Ardalan MR. Marie-François Xavier Bichat (1771-1802) and his contributions to the foundations of pathological anatomy and modern medicine. *Ann Anat.* 2008; 190(5): 413- 420.
03. Madeira MC. *Anatomia da Face-Bases Anátomo-funcionais para a prática odontológica.* 3.ed. São Paulo: Sarvier; 2001. p. 84- 85.
04. Kahn JL, Sick H, Laude M, Koritké JG. The buccal adipose body (Bichat's fat-pad). Morphological study. *Acta Anat.* 1988; 132(1): 41-47.
05. Tostevin PM, Ellis H. The buccal pad of fat: a review. *Clin Anat.* 1995; 8(6): 403-06.
06. Matrasso A. Managing the buccal fat pad. *Aesthetic Surg J.* 2006; 26(3): 330- 36.
07. Stevao ELL. Bichectomy ou Bichatectomy - A small and simple intraoral surgical procedure with great facial results. *Adv Dent & Oral Health.* 2015; 1(1): 001-04.
08. Kopeć T, Wierzbicka M, Szyfter W Stensen's duct injuries: the role of sialendoscopy and adjuvant botulinum. *Wideochir Inne Tech Maloinwazyjne.* 2013; 8(2): 112-6.
09. Castro H. L, Okamoto T, Castro AL. Reação tecidual a alguns tipos de fios de sutura. Avaliação histológica em ratos *Revista da Faculdade de Odontologia.* 1974; 3(1): 101-111.
10. Knight KL. Effects of hypothermia on inflammation and swelling. *Athl. Train. J. Natl. Athl. Train. Assoc.* 1976; 11(1): 7-10.
11. Schaser KD, Disch, AC, Stover, JF, Lauffer A, Bail HJ, Mittlmeier T. Prolonged superficial local cryotherapy attenuates microcirculatory impairment, regional inflammation, and muscle necrosis after closed soft tissue injury in rats. *Am. J. Sports Med.* 2007; 35(1): 93-102.

RESUMO

Bichectomia é um procedimento cirúrgico, intraoral, no qual ocorre a excisão das bolas de Bichat, com o objetivo de afinar o rosto do paciente e conferir maior harmonia do contorno facial. A cirurgia é simples, rápida, e apresenta baixo índice de complicações pós cirúrgicas, podendo ser realizada por cirurgiões dentistas ou cirurgiões plásticos. Neste artigo, será apresentado um relato de caso clínico de um procedimento de

bichectomia em uma paciente do sexo feminino, realizado por cirurgião dentista. Os resultados estéticos desse procedimento podem ser efetivamente observados após um período de 4 a 6 meses, quando o edema do tecido subcutâneo é completamente reabsorvido.

Palavras-chave: Bichectomia; cirurgia de bochecha; bola de Bichat.

CORRESPONDING AUTHOR

Rosivaldo Moreira Júnior
 Instituto Rosivaldo Moreira Júnior
 Rua T-56 Quadra 118 Lote 08 - Setor Bueno - Goiânia - GO
 E-mail: instituto@rosenvaldomoreira.com.br