ROBRAC Revista Odontológica do Brasil Central

Relato de Caso

CBCT findings in recurrent odontogenic keratocyst: implications for diagnosis and treatment

Orlando Aguirre GUEDES[1,2]; Carine CAMPOS[1]; Andreynna Lorrany de Morais FERREIRA[2]; Allisson Filipe Lopes MARTINS[2]; Vinícius Caixeta de SOUSA[2]; Gustavo Silva CHAVES[2]; Artur Aburad de CARVALHOSA[3]; Carlos ESTRELA[4]

1 - Department of Oral Sciences, School of Dentistry, Evangelical University of Goiás, Anápolis, Goiás, Brazil; **2 -** Department of Oral Biology, School of Dentistry, Pontifical Catholic University of Goiás, Goiânia, Goiás, Brazil; **3 -** Department of Oral Sciences, School of Dentistry, University of Cuiabá, Cuiabá, Mato Grosso, Brazil; **4 -** Department of Stomatology, School of Dentistry, Federal University of Goiás, Goiânia, Goiás, Brazil.

Abstract

Odontogenic keratocyst (OKC) is an odontogenic cyst characterized by locally aggressive behavior and a high recurrence rate. This case report describes the role of cone-beam computed tomography (CBCT) in the diagnosis and management of a recurrent OKC. A 29-year-old woman was referred for evaluation because of mild swelling in the right cheek region. Clinical and imaging examinations revealed expansion of the buccal and lingual cortical plates of the right mandible, impacted permanent mandibular canines (#33 and #43), and a large, well-defined unilocular radiolucent lesion extending from teeth #43 to #47. The impacted canines were extracted, and the lesion was surgically enucleated. Histopathological examination confirmed the diagnosis of OKC. Ten months after surgery, panoramic radiography revealed a new radiolucent area at the previously treated site. CBCT demonstrated a well-defined, oval-shaped lesion measuring 45.73 mm mesiodistally and 15.53 mm buccolingually, with buccal cortical perforation and lingual extension involving the region of teeth #44 to #47. Based on the clinical and imaging findings, recurrent OKC was suspected. The patient underwent a second surgical enucleation, accompanied by extraction of teeth #42 to #48. Histopathological examination confirmed recurrence. Subsequent clinical and imaging follow-up revealed no evidence of further recurrence. CBCT provided valuable information regarding lesion extent, cortical involvement, and anatomical relationships, supporting surgical planning and postoperative assessment.

KEYWORDS: Cone-beam Computed Tomography; Odontogenic Keratocyst; Recurrence.

Copyright © 2026 Revista Odontológica do Brasil Central · This work is licensed under a Creative Commons Attribution-NonCommercial-ShareAlike 4.0 International License(CC BY-NC-SA 4.0)

Received: 15/09/26
Accepted: 26/10/26
Published: 19/11/26

DOI: 10.36065/robrac.v35i94.1925

CORRESPONDING AUTHOR
Orlando Aguirre Guedes
Department of Oral Sciences, School of Dentistry, Evangelical University of Goiás, Av. Universitária Km 3,5 – Cidade Universitária, Anápolis, 75083-515 Goiás, Brazil.
E-mail: orlandoaguedes@gmail.com

Introduction

Odontogenic keratocyst (OKC) is a developmental odontogenic cyst characterized by locally aggressive behavior and a high propensity for recurrence[1-3]. It accounts for approximately 3 - 11% of odontogenic cysts[4-7] and predominantly affects individuals in the second and third decades of life[4,5,7,8], with a predilection for the posterior mandible[1-4]. Clinically, OKCs often develop asymptomatically[3,4], extending along the medullary spaces with limited cortical expansion during the early stages[3,4,6]. Radiographically, they typically present as well-defined unilocular or multilocular radiolucencies, occasionally associated with impacted teeth, displacement of adjacent teeth, and cortical perforation[1,2,6,9,10]. Their distinctive biological behavior has been linked to increased epithelial proliferative activity and alterations in the Sonic Hedgehog signaling pathway[2,5,9], whereas characteristic histopathological features include a thin, friable parakeratinized epithelial lining and the possible presence of satellite cysts[2,6,11]. Together, these characteristics contribute to the diagnostic and therapeutic challenges associated with OKC management[2,12].

Recurrence remains a major challenge in the management of OKC and has been attributed to a combination of biological, anatomical, and surgical factors[1,2,9,13]. The persistence of epithelial remnants, the presence of satellite cysts, and difficulties in achieving complete surgical removal may contribute to recurrence, particularly in extensive lesions involving anatomically complex regions[2,8,9,12]. Early detection can be challenging because recurrent lesions may develop asymptomatically within the medullary bone, while postoperative bone remodeling and anatomical superimposition may hinder their identification on conventional radiographs[4,9,12,14]. Although many recurrences occur within the first five years after treatment, late recurrences have been documented decades after the initial intervention[2,4,12]. Consequently, long-term clinical and radiographic surveillance is essential for the early identification of recurrent lesions,

facilitating timely intervention and potentially reducing the morbidity associated with subsequent surgical procedures[15,16].

Cone-beam computed tomography (CBCT) provides valuable complementary information to conventional radiography in the assessment of OKC by enabling three-dimensional visualization of lesion extent and its relationship with adjacent anatomical structures[5,6]. Multiplanar imaging allows detailed evaluation of buccolingual expansion, cortical thinning or perforation, root involvement, and internal lesion architecture without the anatomical superimposition inherent to two-dimensional radiography[6,12]. This additional information may facilitate surgical planning, particularly in extensive or recurrent lesions requiring careful assessment of bone involvement and adjacent anatomical structures[12,16]. During postoperative surveillance, CBCT may also assist in characterizing suspected recurrence and distinguishing postoperative bone remodeling from persistent or recurrent lesions when conventional radiographic findings are inconclusive[6,12]. Therefore, this case report describes the clinical, radiographic, and histopathological findings of a recurrent OKC, emphasizing the contribution of CBCT to lesion assessment, surgical planning, and postoperative surveillance.

Case report

A 29-year-old woman was referred to an oral and maxillofacial diagnostic center (CROIF, Cuiabá, MT, Brazil), with a six-month history of mild swelling in the right cheek region. Her medical, dental, and family histories were unremarkable. Extraoral examination revealed right-sided facial asymmetry, without lymphadenopathy or clinical signs of inflammation. Intraoral examination showed dental malalignment, oral mucosa with no significant alterations, and expansion of the buccal and lingual cortical plates of the right mandibular body. No purulent exudate was observed, and the permanent mandibular canines (#33 and #43) were unerupted. The patient reported no spontaneous pain or other associated symptoms.

Panoramic radiography revealed a large, well-defined unilocular radiolucent lesion with scalloped borders, extending around the tooth roots, extending from the region of the impacted mandibular canines to the distal aspect of tooth #47 (Figure1A). Root resorption involving teeth #44 to #46 and displacement of adjacent tooth roots were also observed. Tooth #46 had previously undergone root canal treatment. Based on the clinical and radiographic findings, the main differential diagnoses included odontogenic cysts or tumors, specifically OKC and unicystic ameloblastoma as the primary considerations.

Considering these, an excisional biopsy was planned. Under local anesthesia, the affected area was surgically exposed. The impacted canines were extracted, and the cystic lesion was enucleated, followed by peripheral ostectomy. The surgical specimen was submitted for histopathological examination, which revealed a cystic lesion lined by a corrugated parakeratinized stratified squamous epithelium, approximately eight cell layers thick. The basal epithelial layer exhibited palisading of hyperchromatic nuclei (Figures 1B and C). No satellite cysts were identified within the fibrous capsule. These histopathological findings confirmed the diagnosis of OKC.

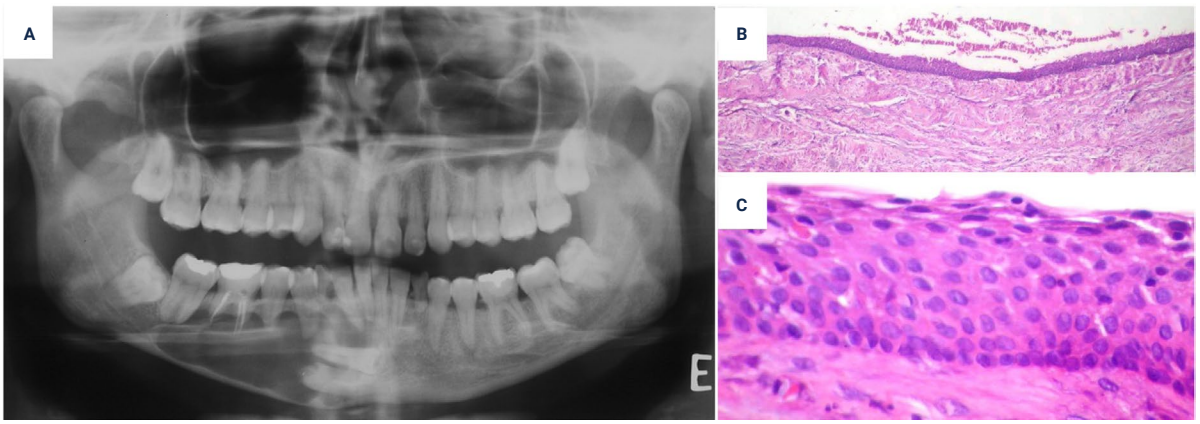

FIGURE 1 · Initial panoramic radiograph showing a large, well-circumscribed unilocular radiolucent lesion extending along the right mandibular body and associated with impacted mandibular canines. **(B)** Low-power photomicrograph showing a cystic lesion lined by parakeratinized stratified squamous epithelium (H&E stain, original magnification ×40). **(C)** High-power photomicrograph demonstrating palisaded hyperchromatic basal cells and parakeratinized epithelial lining characteristic of odontogenic keratocyst (H&E stain, original magnification ×400).

Follow-up appointments at three and five months after surgery revealed no clinical complications. Panoramic radiography showed a marked reduction in the radiolucent area compared with the initial examination (Figure 2A).

At the 10-month follow-up, panoramic radiography revealed a new radiolucent area extending from the mesial aspect of tooth #44 to the mesial root of tooth #47 (Figure 2B). Cone-beam computed tomography (CBCT) was performed using an i-CAT Cone Beam 3D imaging system (Imaging Sciences International, Hatfield, PA, USA). CBCT images revealed a large, well-defined, oval-shaped lesion measuring 45.73 mm mesiodistally and 15.53 mm in the buccolingually (Figure 2C). Coronal sections demonstrated expansion and perforation of the buccal cortical plate and lingual extension of the lesion in the region of teeth #44 to #47 (Figure 2C). Based on these findings and the patient's clinical history, recurrence of the OKC was suspected. The patient subsequently underwent a second surgical procedure involving of enucleation, peripheral osteotomy, and extraction of teeth #42 to #48. Histopathological examination revealed features consistent with those of the initial lesion, confirming the diagnosis of recurrent OKC.

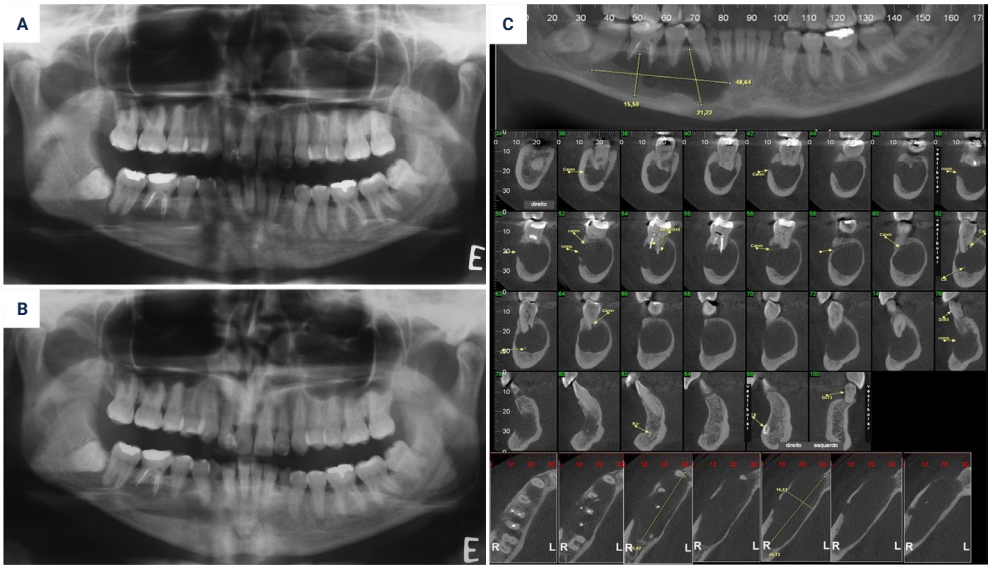

FIGURE 2 · (A) Panoramic radiograph obtained three months after surgery showing initial bone repair and reduction in lesion size. **(B)** Panoramic radiograph obtained 10 months after surgery revealing a new radiolucent area extending from the mesial aspect of tooth #44 to the mesial root of tooth #47. **(C)** CBCT examination obtained after detection of recurrence, demonstrating a well-defined radiolucent lesion with buccal cortical perforation and lingual extension involving the right mandibular body.

Postoperative panoramic radiographs and CBCT examinations obtained 6 months, 1 and 2.5 years after the second surgery revealed no radiographic evidence of further recurrence (Figure 3A to C). No clinical signs of recurrent disease were observed during the follow-up. The patient was referred to rehabilitation and advised of the importance of long-term surveillance because of the high recurrence potential of the OKCs.

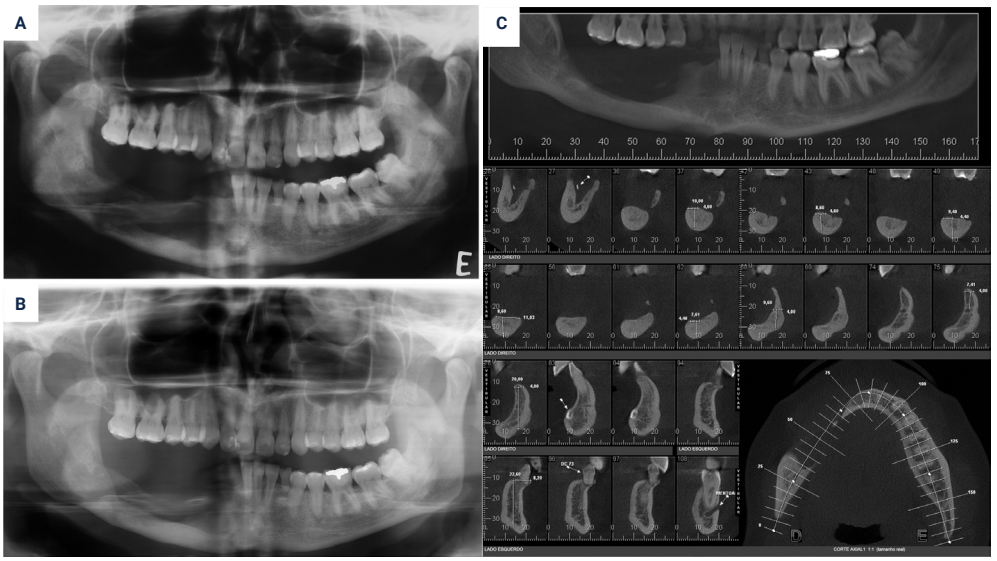

FIGURE 3 · (A) Postoperative panoramic radiograph obtained six months after the second surgical procedure showing satisfactory bone healing. **(B)** Panoramic radiograph obtained one year after treatment without evidence of recurrent lesion. **(C)** CBCT examination obtained 2.5 years after the second surgery demonstrating absence of recurrence and satisfactory bone remodeling.

Discussion

OKC is a benign odontogenic cyst characterized by locally aggressive behavior and a high recurrence rate[1,2,17,18]. It accounts for approximately 3%-12% of odontogenic cysts and tumors and occurs predominantly in the mandible, particularly in its posterior region[5,19]. Although OKC can develop at any age, it is most frequently diagnosed during the second and third decades of life[9,10]. In the present case, a 29-year-old woman presented with an extensive mandibular lesion associated with cortical expansion and impacted teeth, findings consistent with the clinical and radiographic presentation of OKC. The lesion's posterior mandibular location and considerable size highlight the importance

of careful surgical planning and long-term follow-up, particularly given its subsequent recurrence.

The diagnosis of OKC relies on the correlation of clinical, radiographic, and histopathological findings[10,20]. These lesions are often asymptomatic and incidentally detected on routine radiographic examinations, although larger lesions may cause swelling and cortical expansion[3,9]. In the present case, panoramic radiography revealed an extensive, well-defined unilocular radiolucency with scalloped borders, associated with impacted teeth, root resorption, and buccolingual cortical expansion. Although these findings are compatible with OKC, they are not pathognomonic and may also occur in other odontogenic and non-odontogenic lesions[2,21]. Histopathological examination established the definitive diagnosis by demonstrating a parakeratinized stratified squamous epithelial lining with palisaded, hyperchromatic basal cells.

Recurrence remains a major challenge in the management of OKC and may be influenced by both biological characteristics and surgical factors[2,16]. Its high recurrence potential has been attributed to the persistence of epithelial remnants, the presence of satellite microcysts, and the thin, friable epithelial lining, which may complicate complete surgical removal[12,22]. In the present case, although no satellites cysts were identified, recurrence occurred within 10 months of the initial surgery. The considerable size of the lesion may have complicated its complete removal; however, a direct correlation with recurrence cannot be definitively established from the present case alone. We hypothesize that the synergistic combination of an extensive lesion and the characteristically fragile attachment between the epithelial lining and the underlying connective tissue may have resulted in residual epithelial cells being left behind within the bone cavity, likely contributing to the recurrence observed in this case. Although the subsequent histopathological examination confirmed OKC, the relatively short interval between surgical procedures makes it difficult to distinguish true recurrence

from persistence of residual cystic tissue. CBCT examination of the recurrent lesion demonstrated buccal cortical perforation and lingual extension, providing important information about the extent of bone involvement. Previous studies have suggested an association between lesion size, surgical complexity, and recurrence risk[7,23]. Nevertheless, recurrence may occur several years after treatment, emphasizing the need for long-term clinical and radiographic surveillance[3,20].

CBCT is a valuable adjunct to conventional radiography in the assessment of OKC, particularly for determining lesion extent and its relationship with adjacent anatomical structures[18]. Unlike panoramic radiography, CBCT provides multiplanar images without anatomical superimposition inherent to two-dimensional imaging, allowing more detailed evaluation of cortical integrity and buccolingual expansion[5]. In the present case, panoramic radiography revealed a new radiolucent area at the previously treated site, raising suspicion of recurrence. Subsequent CBCT examination demonstrated buccal cortical perforation and lingual extension of the lesion, providing additional anatomical information relevant to surgical planning. These findings highlight the value of CBCT in the assessment of suspected recurrent OKC, particularly when conventional radiographs do not adequately demonstrate the extent of bone involvement[18,19].

Advances in imaging technologies may improve the detection and characterization of recurrent OKC, particularly through refinements in CBCT acquisition protocols and image analysis. Artificial intelligence-based approaches may also offer opportunities for automated lesion detection and assessment, although their clinical applicability requires further validation. Nevertheless, the optimal imaging strategy for long-term surveillance remains uncertain. Further longitudinal studies are needed to establish appropriate follow-up intervals, clarify the indications for CBCT, and determine its contribution to the early detection and management of recurrent OKC.

Conclusion

CBCT provided valuable information for the assessment and surgical planning a recurrent OKC by allowing detailed visualization of lesion extent, cortical perforation, and buccolingual involvement. This case highlights the importance of CBCT as an adjunct to conventional radiography and emphasizes the need for long-term clinical and radiographic follow-up to detect potential recurrence.

References

1 - WHO Classification of Tumours Editorial Board. Head and neck tumours [Internet]. Lyon (France): International Agency for Research on Cancer; 2022. (WHO classification of tumours series, 5th ed.; vol. 9). Available from: https://tumourclassification.iarc.who.int/chapters/52

2 - Mendes RA, Carvalho JF, van der Waal I. Characterization and management of the keratocystic odontogenic tumor in relation to its histopathological and biological features. Oral Oncol. 2010;46(4):219-25.

3 - MacDonald-Jankowski DS. Keratocystic odontogenic tumour: systematic review. Dentomaxillofac Radiol. 2011;40(1):1-23.

4 - Chirapathomsakul D, Sastravaha P, Jansisyanont P. A review of odontogenic keratocysts and the behavior of recurrences. Oral Surg Oral Med Oral Pathol Oral Radiol Endod. 2006;101(1):5-9; discussion 10.

5 - Grasmuck EA, Nelson BL. Keratocystic odontogenic tumor. Head Neck Pathol. 2010;4(1):94-6.

6 - Güler N, Sençift K, Demirkol O. Conservative management of keratocystic odontogenic tumors of jaws. ScientificWorldJournal. 2012;2012:680397.

7 - Buckley PC, Seldin EB, Dodson TB, August M. Multilocularity as a radiographic marker of the keratocystic odontogenic tumor. J Oral Maxillofac Surg. 2012;70(2):320-4.

8 - Myoung H, Hong SP, Hong SD, Lee JI, Lim CY, Choung PH, et al. Odontogenic keratocyst: Review of 256 cases for recurrence and clinicopathologic parameters. Oral Surg Oral Med Oral Pathol Oral Radiol Endod. 2001;91(3):328-33.

9 - Habibi A, Saghravanian N, Habibi M, Mellati E, Habibi M. Keratocystic odontogenic tumor: a 10-year retrospective study of 83 cases in an Iranian population. J Oral Sci. 2007;49(3):229-35.

10 - Cakur B, Miloglu O, Yolcu U, Goregen M, Gursan N. Keratocystic odontogenic tumor invading the right maxillary sinus: a case report. J Oral Sci. 2008;50(3):345-9.

11 - Kuroyanagi N, Sakuma H, Miyabe S, Machida J, Kaetsu A, Yokoi M, et al. Prognostic factors for keratocystic odontogenic tumor (odontogenic keratocyst): analysis of clinico-pathologic and immunohistochemical findings in cysts treated by enucleation. J Oral Pathol Med. 2009;38(4):386-92.

12 - Morgan TA, Burton CC, Qian F. A retrospective review of treatment of the odontogenic keratocyst. J Oral Maxillofac Surg. 2005;63(5):635-9.

13 - Gonzalez-Alva P, Tanaka A, Oku Y, Yoshizawa D, Itoh S, Sakashita H, et al. Keratocystic odontogenic tumor: a retrospective study of 183 cases. J Oral Sci. 2008;50(2):205-12.

14 - Zecha JA, Mendes RA, Lindeboom VB, van der Waal I. Recurrence rate of keratocystic odontogenic tumor after conservative surgical treatment without adjunctive therapies - A 35-year single institution experience. Oral Oncol. 2010;46(10):740-2.

15 - Maurette PE, Jorge J, de Moraes M. Conservative treatment protocol of odontogenic keratocyst: a preliminary study. J Oral Maxillofac Surg. 2006;64(3):379-83.

16 - Johnson NR, Batstone MD, Savage NW. Management and recurrence of keratocystic odontogenic tumor: a systematic review. Oral Surg Oral Med Oral Pathol Oral Radiol. 2013;116(4):e271-6.

17 - Gomes CC, Diniz MG, Gomez RS. Review of the molecular pathogenesis of the odontogenic keratocyst. Oral Oncol. 2009;45(12):1011-4.

18 - Kocak-Berberoglu H, Cakarer S, Brkic A, Gurkan-Koseoglu B, Altug-Aydil B, Keskin C. Three-dimensional cone-beam computed tomography for diagnosis of keratocystic odontogenic tumours; evaluation of four cases. Med Oral Patol Oral Cir Bucal. 2012;17(6):e1000-5.

19 - Apajalahti S, Hagstrom J, Lindqvist C, Suomalainen A. Computerized tomography findings and recurrence of keratocystic odontogenic tumor of the mandible and maxillofacial region in a series of 46 patients. Oral Surg Oral Med Oral Pathol Oral Radiol Endod. 2011;111(3):e29-37.

20 - Schussel JL, Stramandinoli RT, Dissenha JL, Avila LF, Sassi LM. Retrospective study of 25 cases of keratocystic odontogenic tumor: epidemiology and treatment. J Contemp Dent Pract. 2011;12(2):100-3.

21 - Titinchi F, Nortje CJ. Keratocystic odontogenic tumor: a recurrence analysis of clinical and radiographic parameters. Oral Surg Oral Med Oral Pathol Oral Radiol. 2012;114(1):136-42.

22 - Abdullah WA. Surgical treatment of keratocystic odontogenic tumour: A review article. Saudi Dent J. 2011;23(2):61-5.

23 - Boffano P, Ruga E, Gallesio C. Keratocystic odontogenic tumor (odontogenic keratocyst): preliminary retrospective review of epidemiologic, clinical, and radiologic features of 261 lesions from University of Turin. J Oral Maxillofac Surg. 2010;68(12):2994-9.

Achados tomográficos em ceratocisto odontogênico recorrente: implicações diagnósticas e terapêuticas

Resumo

O ceratocisto odontogênico (CO) é um cisto odontogênico caracterizado por comportamento localmente agressivo e elevada taxa de recorrência. Este relato de caso descreve o papel da tomografia computadorizada de feixe cônico (TCFC) no diagnóstico e tratamento de um CO recorrente. Uma paciente de 29 anos foi encaminhada para avaliação devido a um discreto aumento de volume na região direita da face. Os exames clínicos e por imagem revelaram expansão das corticais ósseas vestibular e lingual da mandíbula direita, caninos inferiores permanentes inclusos (dentes 33 e 43) e uma extensa lesão radiolúcida unilocular, bem delimitada, estendendo-se da região do dente 43 ao 47. Os caninos inclusos foram extraídos e a lesão foi submetida à enucleação cirúrgica. O exame histopatológico confirmou o diagnóstico de CO. Dez meses após a cirurgia, a radiografia panorâmica revelou uma nova área radiolúcida na região previamente tratada. A TCFC evidenciou uma lesão ovalada, bem delimitada, medindo 45,73 mm no sentido mesiodistal e 15,53 mm no sentido vestibulolingual, com perfuração da cortical vestibular e extensão lingual, envolvendo a região dos dentes 44 a 47. Com base nos achados clínicos e imaginológicos, suspeitou-se de recorrência do CO. A paciente foi submetida a uma segunda enucleação cirúrgica, acompanhada da exodontia dos dentes 42 a 48. O exame histopatológico confirmou a recorrência da lesão. O acompanhamento clínico e imaginológico subsequente não revelou evidências de novas recorrências. A TCFC forneceu informações relevantes sobre a extensão da lesão, o comprometimento das corticais ósseas e suas relações com as estruturas anatômicas adjacentes, contribuindo para o planejamento cirúrgico e a avaliação pós-operatória.

PALAVRAS-CHAVE: Ceratocisto Odontogênico; Recorrência; Tomografia Computadorizada de Feixe Cônico.

How to cite this paper

Guedes OA, Campos C, Ferreira ALM, Martins AFL, Sousa VC, Chaves GS, Carvalhosa AA, Estrela C. CBCT findings in recurrent odontogenic keratocyst: implications for diagnosis and treatment. Rev Odontol Bras Central 2026; 35(94): 124-134. DOI: 10.36065/robrac.v35i94.1925