

Computed tomography as legal evidence of malpractice in dentomaxillofacial Implantology: report of a case series

Tomografia computadorizada como evidência legal em Implantodontia: uma série de casos

Ademir FRANCO¹; Mário M. FERNANDES^{2,3}; Alessandra KICHLER³; Juan C. Z. RODRÍGUEZ⁴; Rógerio N. OLIVEIRA²

1 - Forensic Dentistry, Department of Oral Health Sciences, Catholic University Leuven, Belgium.

2 - Forensic Dentistry, Department of Community Dentistry, School of Dentistry, Universidade de São Paulo, SP, Brazil.

3 - Department of Forensic Dentistry, Brazilian Dental Association (Rio Grande do Sul Section), Porto Alegre, RS, Brazil.

4 - Forensic Odontology, Autonomous University of Paraguay, Paraguay.

ABSTRACT

Objective: To report three cases of neural injuries during dental implant placement. **Material and methods:** In 2014, three female patients aged 59 (A); 60 (B); and 70 (C) years old were referred for legal investigation of malpractice during implant placement. Seven implants were placed in patient A; three implants were placed in patient B; and seven implants were placed in patient C. Postoperative computed tomography of the patients revealed injury signs of the inferior alveolar nerve. Clinically, the patients referred lack of sensitivity in the soft tissue adjacent to

the surgical site. **Results:** All the presented cases culminated in legal suits. Consequently, the dentists involved with patients A and B are awaiting respective trials, while the dentist involved with patient C was already condemned. **Conclusion:** The present study highlights the need for optimal preoperative planning; careful transoperative performance; and adequate postoperative follow-up. Based on that, oral and maxillofacial injuries and legal consequences may be avoided in Implantology.

KEYWORDS: Dental implant; Computed Tomography; Malpractice; Mandibular Nerve; Jurisprudence.

INTRODUCTION

Dentomaxillofacial Implantology became a developed branch of Dentistry in the last decades, enabling oral rehabilitation worldwide. Consequently, the number of practitioners performing implant surgeries proportionally increased¹, potentiating the risk for accidents and complications.

In general dentistry, more than 70% of practitioners already experienced patients with nerve injury due to oral interventions². Specifically in Implantology, reports on the prevalence rate for nerve injuries ranges from 0 up to 40%³. Mostly, the inferior alveolar nerve (IAN) is involved in accidents during implant placement, culminating in a deficit of adjacent sensitive activity. According to Seddon⁴ (1942), nerve injuries are classified into: 1) neurotmesis; 2) axonotmesis; and 3) neurapraxia. Neurotmesis characterizes completely divided nerves due to local trauma; axonotmesis comprehends the degeneration of peripheral fibers of the nerve, maintaining the continuity of intimate supporting structures; and neurapraxia indicates that the nerve remains intact, but neural activities become blocked due to low intensity trauma.

The neural healing process highly depends on the etiology and type of nerve injury. Mainly, it may occur spontaneously or through medical intervention, such as the microneurosurgical anastomosis⁵ and the local decompression⁶. Currently, high-tech imaging devices and advanced technical knowledge represent tools for optimal surgical plan, avoiding potential accidents. Despite that, malpractice persists in the routine of dentomaxillofacial Implantology; patients remain injured; and legal demands fill up the medical jurisprudence. The present study

aims to report three cases of malpractice involving traumatic injury to the IAN during implant placement.

CASE REPORTS

In 2014, three female patients aged 59 (A); 60 (B); and 70 (C) years old were referred from the legal courts to forensic odontologists for the investigation of potential malpractice during surgery for dentomaxillofacial implant placement.

Patient A had oral rehabilitation treatment with a combination of 1 zygomatic; 3 maxillary; and 3 mandibular implants. The surgical procedure was planned on a panoramic radiograph and performed under local anesthesia by a general dentist. According to the initial panoramic radiograph, patient A presented a severe level of periodontal disease in both dental arches. Specifically, the maxillary right second molar (#17), second premolar (#15) and canine (#13); and the maxillary left second molar (#27) were planned for extraction prior to implant placement. The mandibular arch revealed bilateral edentulous areas on premolar and molars sites. Oral implants were placed on the region of teeth #15, #13, #23, #36, #44, #46. A zygomatic implant was placed on the region of tooth #17. After the surgery, the patient noticed a prolonged lack of sensitivity on the right side of the mandible followed by local tingling. Additionally, the patient referred retraction of facial skin around the right eye. The exams on postsurgical cone beam computed tomography revealed signs of injury to the IAN and to the floor of the orbit. Specifically, the implant placed on the region of tooth #44 invaded the mandibular canal (Figure 1A), while the zygomatic implant penetrated the inferior bone limit of the orbit (Figure 1B).

The patient underwent a new surgery in order to remove both implants. A legal suit was established against the dentist responsible for the implant placement. The dentist awaits a legal trial.

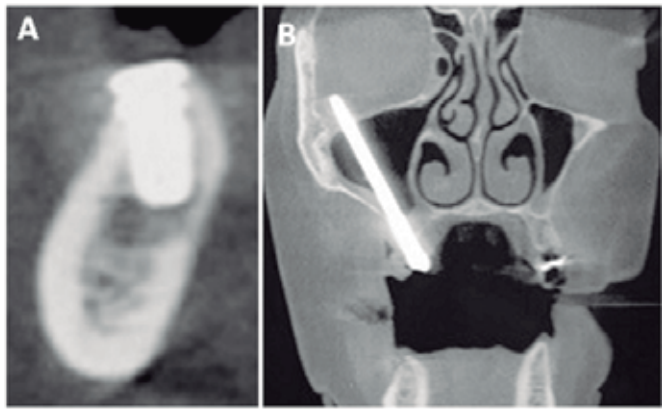


Figura 1 - Patient A: (A) Sagittal slice of computed tomography illustrating the close relation between the implant and the mandibular canal; (B) Coronal view of the zygomatic implant transposing the inferior bone limit of the right orbit.

Patient B was edentulous from the mandibular right second premolar to the mandibular right second molar (#45, #46, #47). The surgical procedure was planned on cone beam computed tomography and consisted of placing 3 oral implants in the edentulous area under local anesthesia. One day after the surgery the patient returned to the dentist reporting lack of sensitivity and tingling on the lower lip, and spontaneous pain on the right side of the face. A new computed tomography revealed that two implants penetrated into the space of the mandibular canal (Figures 2A and B). The patient was referred for a new surgery in order to replace the previous implants (10 mm length) for shorter implants. However, in the next morning, the patient woke up with both implants out of site, floating into the mouth. The symptoms persisted requiring a third surgery to remove the remaining implant. The patient was referred for lower-level laser therapy and acupuncture treatment under the supervision of a neurologist. Seven months after the alternative treatments, the patients started controlling the symptoms under the prescription of Carbamazepine (Tegretol® CR 200mg, Novartis, Switzerland). A legal suit was established against the dentist in order to repair the reported damages. The dentist awaits a legal trial.

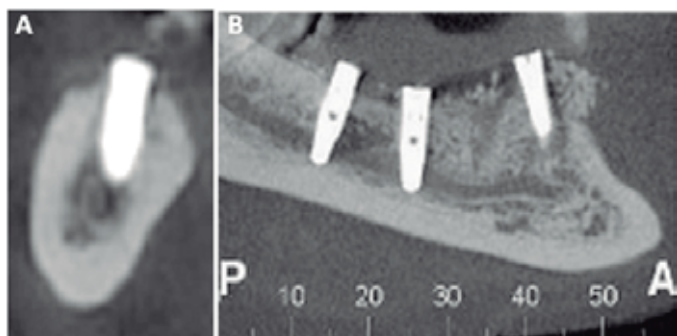


Figura 2 - Patient B: (A) Sagittal slice of computed tomography illustrating the close relation between the implant and the mandibular canal; (B) Panoramic reconstruction from computed tomography revealing two posterior implants transposing the limits of the right mandibular canal.

Patient C presented edentulous mandible with horizontal bone loss. The surgical procedure was planned on a panoramic radiograph and consisted of placing 6 oral implants under local anesthesia. After the surgery, the patient reported inflammation in the periodontal tissue; constant food impaction; inadequate aesthetic arrangement and lack of sensitivity and tingling in the left side of the mandible and adjacent soft tissue. A postsurgical multislice computed tomography showed that all the internal hexagon implants remained partially exposed into the mouth (Figure 3A). Additionally, the most posterior implant on the left side of the mandible was in contact with the mandibular canal (Figure 3B). Clinically, a single prosthetic component with 13 dental crowns was detected improperly attached to the 6 oral implants together with compromised periodontal status and aesthetics. A legal suit was established against the dentist culminating in condemnation based on moral and material purposes.

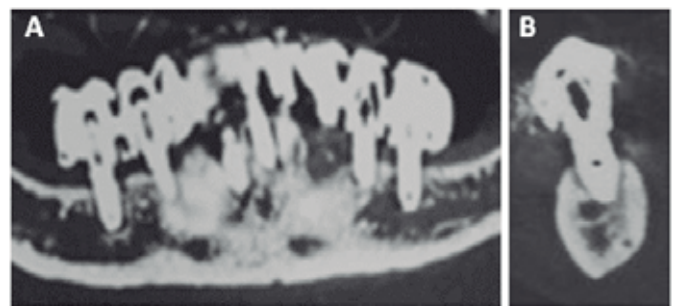


Figura 3 - Patient C: (A) Panoramic reconstruction from computed tomography revealing improper bone anchorage in the mandible; (B) Sagittal slice of computed tomography illustrating the close relation between the implant and the mandibular canal.

DISCUSSION

The potential risks involved within dentomaxillofacial implant placement are highly related to the preoperative, transoperative and postoperative stages. Specifically, the preoperative stage enables a broad range of decisions in order to avoid potential accidents. Yet, accidents may happen during the transoperative stage, in which the technical performance is applied. Finally, the postoperative stage allows for possible complications which may arise from inadequate medication or follow-up⁷.

In the present report of case series, the preoperative surgical planning illustrates a unique situation in which the most complex rehabilitations were planned on panoramic radiographs (patients A and C); while the simplest rehabilitation was planned in cone beam computed tomography (patient B). The medical literature describes the extensive advantages of using computed tomography prior to surgical procedures. Mainly, the possibility of investigating the bone morphology in detail is often highlighted⁸. Maqbool *et al.*⁸ (2013), illustrate the essential role of CBCT reporting a case of injury to an accessory branch of the IAN. Yet Yilmaz *et al.*⁹ (2012), reported two clinical cases in which misplaced implants were detected only through postoperative computed tomography. The same was observed in our case series, in which computed tomography played the main role providing legal evidence in order to support the expertises requested by the courts.

In addition, patients A and C presented severe level of bone loss, which potentially lacks an adequate anchorage. Clearly, a proper examination of the implant surgical site also could be achieved using preoperative computed tomography. The lack of alveolar bone thickness also made necessary the rehabilitation of patient A with a complex zygomatic implant. Newman *et al.*¹⁰ (2006), highlight the need for referring complex cases involving oral implant to specialists, indicating that potential complications may occur. Oppositely, Patient A was operated by a general dentist, consequently culminating in orofacial injuries. Reychler and Oslzewski¹¹ (2010), also illustrate accidents involving zygomatic dental implant placement reporting a unique situation of intracerebral penetration of a displaced implant. Additionally to great technical expertise and experience, the authors indicate pre- and postoperative computed-assisted imaging in order to reach optimal surgical plans and follow-up.

Postoperative computed tomography of the 3 cases revealed implant penetration in the space of mandibular canal, consequently damaging the Inferior Alveolar Nerve. According to the classification of Seddon⁴ (1942), these injuries characterize axonotmesis, in which the neurovascular bundle remains continuous presenting peripheral degeneration. Consequently, the patients developed local paresthesia. Approximately 73% of the patients with neural injuries present paresthesia. Similarly, Renton and Yilmaz¹² (2011), profiled 90 with IAN injury revealing that approximately 70% of the patients with neuropathy presented paresthesia. One year later, the same authors expressed own clinical managements and outcomes for 123 patients with IAN. Mostly, the clinical approaches consisted of therapeutic counseling (51%). Other patients were treated with cognitive behavior therapy; palliative pain care; and exploratory surgeries¹³. In our study, the iatrogenic nerve injury caused in patient A was managed with a new surgery for the removal of oral implants; while patient C did not receive any postoperative care. Yet patient B was treated with surgeries for implant replacement and removal; lower-level laser therapy; acupuncture; and administration of Carbamazepine. The medical literature indicates alternative approaches, such as lower-level laser therapy¹⁴ acupuncture may induce sensitive recovery of the IAN in injured patients. Opposite to the literature, patient B did not report sensitive improvements. On the other hand, the prescription of anticonvulsants, such as Carbamazepine, played an effective role as a palliative care. However, the alternative approaches abovementioned must be indicated and followed by neurologists.

CONCLUSION

Optimal clinical care for candidates of dentomaxillofacial implant placement must start from an adequate preoperative plan, preferably through high-tech computer-assisted imaging devices. Additionally, trained surgeons with advanced technical knowledge must perform transoperative procedures avoiding potential accidents. Finally, postoperative follow-ups must be systematically implemented in order to detect any complication or adverse condition. In this context, dental surgeons protect the patient's health acting within ethics and proper clinical behavior in the routine of Implantology.

REFERENCES

1. Worthington P. Medicolegal aspects of oral implant surgery. *Aust Prosthodont J.* 1995; 9(Suppl): 13-7.
2. Misch CE, Resnik R. Mandibular nerve neurosensory impairment after dental implant surgery: management and protocol. *Implant Dent.* 2010; 19(5): 378-86.
3. Joudzbalys G, Wang HL, Sabalys G. Injury of the inferior alveolar nerve during implant placement: a literature review. *J Oral Maxillofac Res.* 2011; 2(1): e1.
4. Seddon HJ. A classification of nerve injuries. *Br Med J.* 1942; 2(4260): 237-9.
5. Pogrel MA. The results of microneurosurgery of the inferior alveolar and lingual nerves. *J Oral Maxillofac Surg.* 2002; 60(5): 485-9.
6. Marques TM, Gomes JM. Decompression of inferior alveolar nerve: case report. *J Can Dent Assoc.* 2011; 77(1): 34.
7. Pitrez F. Medical malpractice—the surgeon's view. *Rev Col Bras Cir.* 2012; 39(3): 171-2.
8. Maqbool A, Sultan AA, Bottini GB, Hopper C. Pain caused by a dental implant impinging on an accessory inferior alveolar canal: a case report. *Int J Prosthodont.* 2013; 26(2): 125-6.
9. Yilmaz B, Ozcelik BT, Sarantopoulos DM, McGlumphy E. Importance of CT scans in diagnosing symptoms from misplaced implants. *Implant Dent.* 2012; 21(2): 108-11.
10. Newman MG, Takei H, Klokkevold PR, Carranza FA. *Carranza's clinical periodontology.* Philadelphia: Saunder Elsevier; 2006. 872 p.
11. Reychler H, Oslzewski R. Intracerebral penetration of a zygomatic dental implant and consequent therapeutic dilemmas: case report. *Int J Oral Maxillofac Implants.* 2010; 25(2): 416-8.
12. Renton T, Yilmaz Z. Profiling of patients preserving with posttraumatic neuropathy of the trigeminal nerve. *J Orofac Pain.* 2011; 25(4): 333-44.
13. Renton T, Yilmaz Z. Managing iatrogenic trigeminal nerve injury: a case series and review of the literature. *Int J Oral Maxillofac Surg.* 2012; 41(5): 629-37.
14. Führer-Valdivia A, Noguera-Pantoja A, Ramírez-Lobos V, Solé-Ventura P. Lower-level laser effect in patients with neusensory impairment of the mandibular nerve after sagittal split ramus osteotomy. Randomized clinical trial controlled by placebo. *Med oral Patol Oral Cir Bucal.* 2014; 19(4): 327-34.

RESUMO

Objetivo: Relatar três casos clínicos envolvendo danos neurológicos decorrentes da instalação de implantes dentários. **Materiais e métodos:** Em 2014, três pacientes do sexo feminino de 59 (A); 60 (B); e 70 (C) anos de idade foram encaminhadas para exame pericial odontológico tendo como objetivo a investigação de dano neurológico decorrente da falha na instalação de implantes. Sete implantes foram instalados na paciente A; três implantes foram instalados na paciente B; e sete implantes foram instalados na paciente C. Clinicamente, todas as pacientes referiram perda de sensibilidade nas regiões adjacentes aos sítios cirúrgicos. Todos os pacientes foram submetidos à tomografia computadorizada pós-operatória, revelando sinais de invasão de espaço do canal mandibular. **Resultados:** Todos os casos resultaram em ações judiciais demandadas contra os profissionais. Consequentemente, houve a condenação do profissional envolvido no tratamento da paciente C, enquanto os profissionais en-

volvidos nos demais casos aguardam julgamento. Conclusão: O presente estudo ressaltou a importância do correto planejamento pré-operatório; dos cuidados técnicos transoperatórios; e dos corretos acompanhamentos clínico e radiográfico pós-operatório.

Assim, danos orais e maxilofaciais poderão ser potencialmente evitados na rotina cirúrgica dos profissionais de Implantodontia.

PALAVRAS-CHAVE: Implantes dentários; Tomografia computadorizada; Imperícia; Nervo mandibular; Jurisprudência.

CORRESPONDING AUTHOR

Katholieke Universiteit Leuven, Forensic Odontology,
Department of Oral Health Science, Faculty of Medicine.
Kapucijnenvoer 7
3000 - Leuven, - Bélgica
E-mail: franco.gat@gmail.com